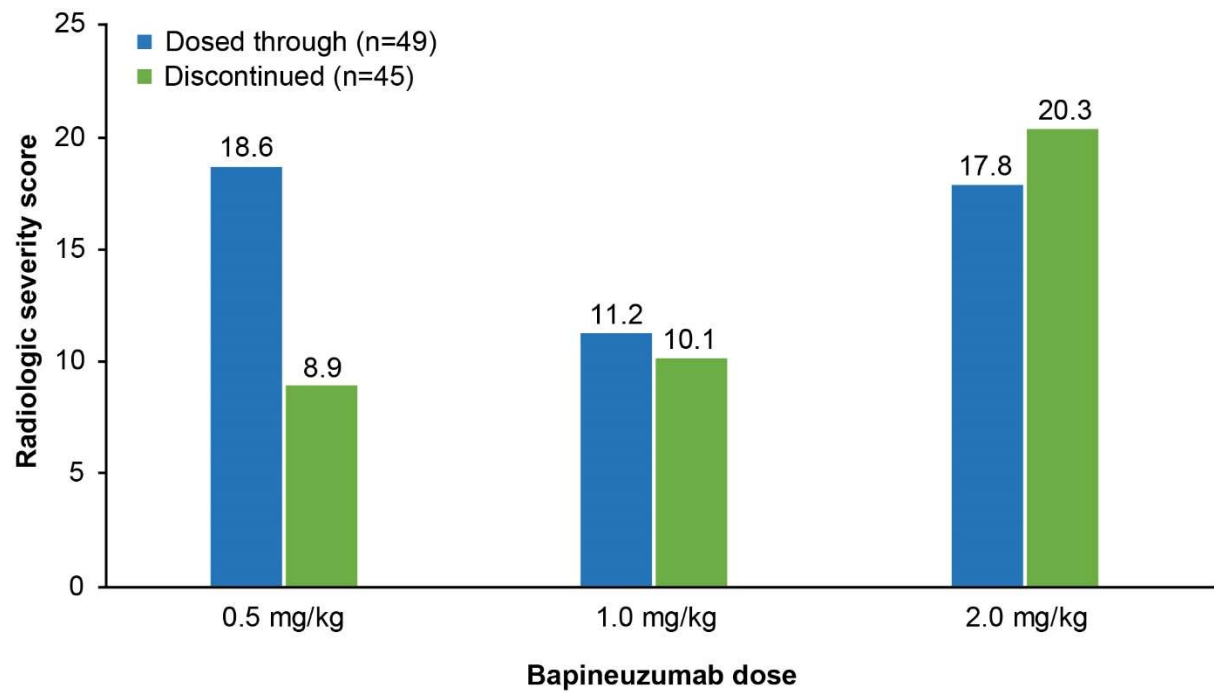


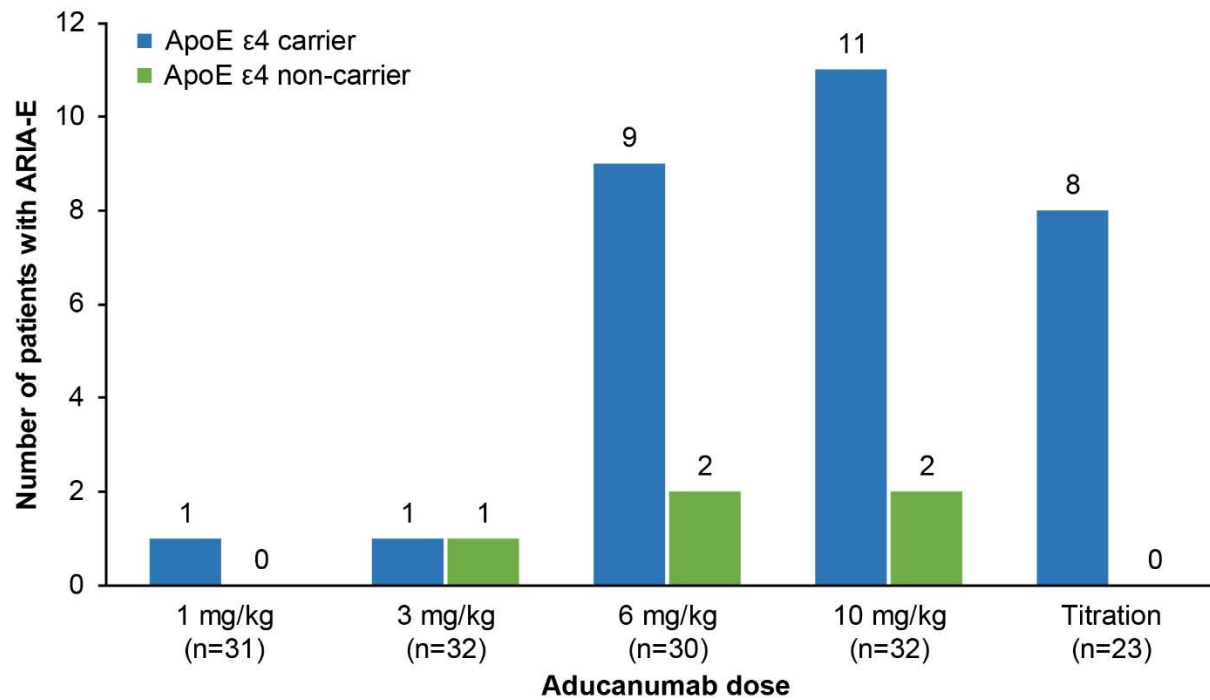
## Supplementary material

**Supplementary Figure 1.** Total maximum mean ARIA-E radiographic severity scores in patients who discontinued bapineuzumab treatment vs patients who were dosed through ARIA [25]



ARIA, amyloid-related imaging abnormalities; ARIA-E, amyloid-related imaging abnormalities due to vasogenic edema, sulcal effusions

**Supplementary Figure 2.** Number of ARIA-E events in a phase 1b clinical trial of aducanumab. The dose titration arm involved 1 mg/kg for the first two infusions, 3 mg/kg for four infusions, 6 mg/kg for a subsequent five infusions, and 10 mg/kg thereafter [10,23]



ApoE, apolipoprotein E; ARIA-E, amyloid-related imaging abnormalities due to vasogenic edema, sulcal effusions